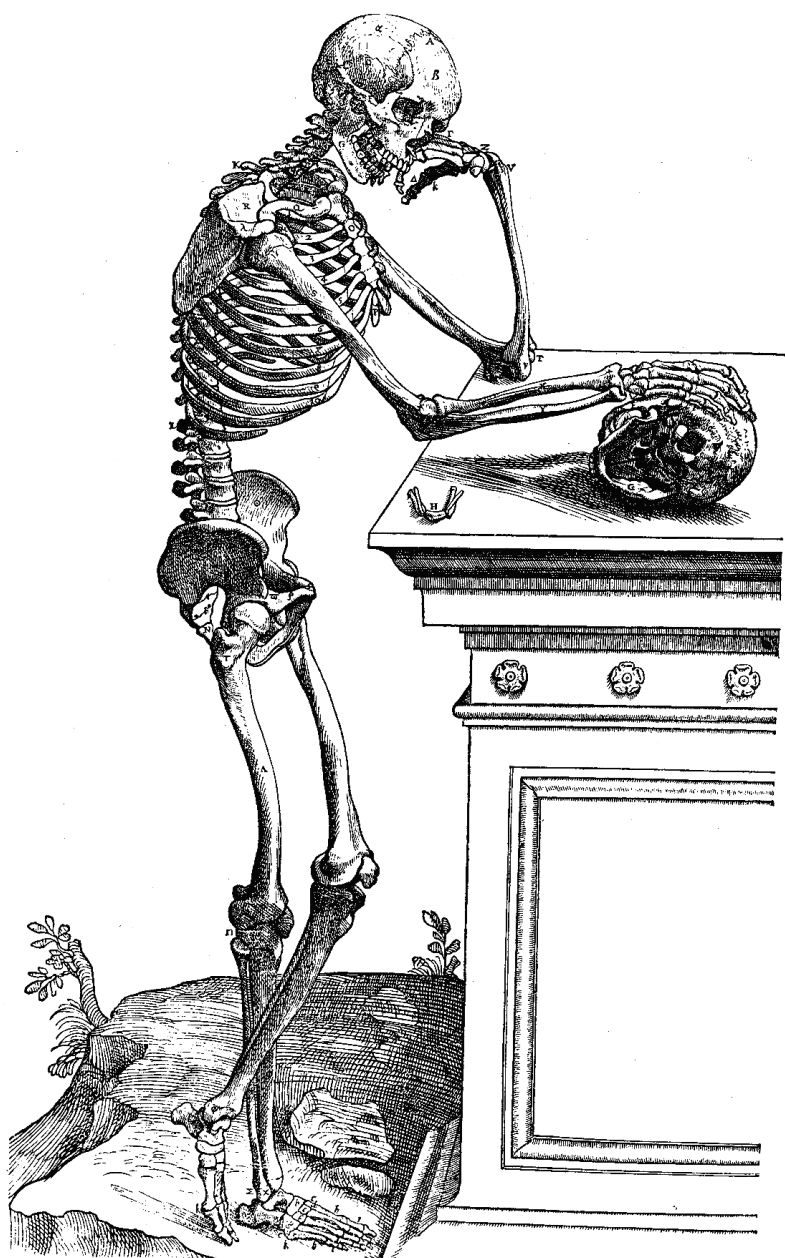


# TRANSITION ANALYSIS AGE ESTIMATION: SKELETAL SCORING MANUAL

Fordisc Version 1.02  
August 2016



George R. Milner<sup>1</sup>

and

Jesper L. Boldsen<sup>2</sup>

<sup>1</sup> The Pennsylvania State University  
University Park, PA USA

<sup>2</sup> Syddansk Universitet  
Odense, DK

## Abbreviated Scoring Procedure

This list of anatomical features and stages is for individuals who are already familiar with the criteria used for each trait. It helps reduce inadvertent errors that occur when an observer's memory fails or confusion sets in when scoring many skeletons in short order. Practiced observers are likely to rely mostly on the following several pages, referring to the detailed descriptions as needed.

### Cranial Sutures

#### *Coronal Pterica (left)*

##### Characteristics

1. Open
2. Juxtaposed
3. Partially obliterated
4. Punctuated
5. Obliterated

#### *Sagittal Obelica*

##### Characteristics

1. Open
2. Juxtaposed
3. Partially obliterated
4. Punctuated
5. Obliterated

#### *Lambdoidal Asterica (left)*

##### Characteristics

1. Open
2. Juxtaposed
3. Partially obliterated
4. Punctuated
5. Obliterated

#### *Zygomaticomaxillary suture (left)*

##### Characteristics

1. Open
2. Juxtaposed
3. Partially obliterated
4. Punctuated
5. Obliterated

#### *Interpalatine (posterior median palatine)*

##### Characteristics

1. Open (open and juxtaposed)
3. Partially obliterated
4. Punctuated
5. Obliterated

## Pubic Symphysis

### *Topography*

#### Location

Entire surface

#### Characteristics

1. Sharp billowing
2. Soft, deep billowing
3. Soft, shallow billowing
4. Residual billowing
5. Flat
6. Irregular

### *Dorsal Texture*

#### Location

Dorsal half (demiface)

#### Characteristics

1. Smooth (fine grained)
2. Coarse grained
3. Microporosity
4. Macroporosity

### *Superior Protuberance*

#### Location

Superior part of the symphyseal face

#### Characteristics

1. No protuberance
2. Early protuberance
3. Late protuberance
4. Integrated

### *Ventral Margin*

#### Location

Ventral margin

#### Characteristics

1. Serrated
2. Beveled
3. Rampart formation
4. Rampart completion with anterior sulcus
5. Rampart completion without sulcus
6. Rim
7. Breakdown

### *Dorsal Margin*

#### Location

Dorsal half (demiface)

#### Characteristics

1. Serrated
2. Flattening incomplete
3. Flattening complete
4. Rim
5. Breakdown

## Auricular Area

### *Superior demiface topography*

#### Location

Superior demiface

#### Characteristics

1. Undulating
2. Median elevation
3. Flat to irregular

### *Inferior demiface topography*

#### Location

Inferior demiface

#### Characteristics

1. Undulating
2. Median elevation
3. Flat to irregular

### *Superior surface characteristics*

#### Location

Superior part of the auricular surface

#### Characteristics

1. >2/3 covered by billows
2. 1/3-2/3 covered by billows
3. <1/3 covered by billows
4. Flat (no billows)
5. Bumps

### *Middle surface characteristics*

#### Location

Middle (apical) part of the auricular surface

#### Characteristics

1. >2/3 covered by billows
2. 1/3-2/3 covered by billows
3. <1/3 covered by billows
4. Flat (no billows)
5. Bumps

### *Inferior surface characteristics*

#### Location

Inferior part of the auricular surface

#### Characteristics

1. >2/3 covered by billows
2. 1/3-2/3 covered by billows
3. <1/3 covered by billows
4. Flat (no billows)
5. Bumps

### *Inferior surface texture*

#### Location

Inferior part

#### Characteristics

1. Smooth
2. Microporosity
3. Macroporosity

### *Superior posterior iliac exostoses*

#### Location

Superior part of the posterior ilium

#### Characteristics

1. Smooth
2. Rounded exostoses
3. Pointed exostoses
4. Jagged exostoses
5. Touching exostoses
6. Fusion

### *Inferior posterior iliac exostoses*

#### Location

Inferior part of the posterior ilium

#### Characteristics

1. Smooth
2. Rounded exostoses
3. Pointed exostoses
4. Jagged exostoses
5. Touching exostoses
6. Fusion

### *Posterior exostoses (or spicules)*

#### Location

Posterior to the sacroiliac joint

#### Characteristics

1. Smooth (no exostoses or spicules)
2. Rounded exostoses
3. Pointed exostoses

## Introduction

This manual covers how to record three skeletal features – the pubic symphysis, iliac portion of the sacroiliac joint, and cranial sutures – used to estimate the ages of adults with the Transition Analysis computer program. Beginning in 1996, we developed new scoring systems for age-progressive changes in bony morphology and examined two known age-at-death skeletal collections (Terry and Coimbra) to estimate the age distribution associated with each of the new stages that were defined. The program calculates estimated ages (maximum likelihoods) and confidence intervals for archaeological or forensic skeletons. Further explanation of the procedure can be found in Boldsen et al. (2002), and the results of a validation study in Milner and Boldsen (2012).

Not all skeletal traits have to be present to generate an age estimate. That is, the procedure was designed to accommodate the possibility that only a partial skeleton is available for observation.

### *Trait location*

It is essential to score only what is happening in the location specified in each of the descriptions, and not be influenced by the appearance of the anatomical unit as a whole. That is because the ages of transition for the young to old stages pertain to specific parts of the anatomical units under consideration. Nonsensical results will result from inattention to adhering to the scoring locations.

### *Ambiguous skeletal features*

Occasionally it is difficult or impossible to distinguish between sequential stages in one or more components. Skeletal features might be altered by pathological processes or eroded after burial. There is still information, however, in such characters.

Osteologists should record whatever is observable, using a two or more stage designation as appropriate (e.g., Stages 3-4). Doing so allows one to take full advantage of the meager information that might be available in the bony structure that is being scored. For example, a partly observable pubic symphysis ventral margin that has at least 1 cm of a rim visible would be scored as Rim (6) and Breakdown (7). The 6-7 score is appropriate because it is known a rim is present,

but there might have been sufficient breakdown in the margin segment that is missing to be classified as Breakdown (7).

When a particular component cannot be observed it should be coded as unscorable. Usually such situations arise when there is postmortem damage. But sometimes that can happen as a result of antemortem alterations to normal skeletal structures. For example, large parity pits can eat deeply into the dorsal portion of the pubic symphysis of females, eliminating features that otherwise could be scored.

### *Traits and ages*

Most stages are used for age estimation, although several are combined or omitted within the computer program. That is, the recorder does not have to be concerned with these details. Just score what you see.

## Cranial Sutures

The suture closure scores are similar to what osteologists have used for over a century. As far as the vault is concerned, ectocranial suture closure is recorded because it is often difficult to examine the interiors of archaeological crania, which can be dirty. Suture segment names conform to those commonly used by osteologists. Palatal sutures are included largely because they have been shown to be of some use in age estimation, even though they are often damaged (Mann et al. 1987).

### Scoring Tips

For sake of completeness, it is a good practice to record closure of both the left and right coronal, lambdoidal, and zygomaticomaxillary sutures, if present. When entering data, it is possible to list scores for both sides if they are different. Although Transition Analysis is based on the left side, the inclusion of scores for both bilateral sutures is conservative as it, in effect, increases the age interval. Because sutures are notoriously poor indicators of age, wider intervals are not a bad outcome.

The first stage, Open, is perhaps best seen in Lambdoidal Asterica. It is, in fact, a common score for that suture segment, especially in young adults. It even occurs in middle-aged adults. The Open category is distinguished from Juxtaposed by a noticeable gap between the two adjoining bones. The width of this gap varies from one suture to another, although it is generally greatest at Lambdoidal Asterica. While there is no bony bridging of the suture in the Juxtaposed category, the two adjacent bones are only separated by a narrow line, just as if a line was drawn on the bone by a pencil with a thin lead.

## Coronal Pterica

### Location

Score the most inferior section of the coronal suture, a relatively straight part without a meandering appearance. It typically extends from the temporal line inferiorly to the sphenoid.

### Characteristics

1. Open
2. Juxtaposed
3. Partially obliterated

4. Punctuated
5. Obliterated

### Definitions

1. *Open*: The suture is visible along its entire length, and there is a noticeable gap between the bones.

2. *Juxtaposed*: The suture is visible along its entire length, but the suture is narrow because the bones are tightly juxtaposed. If there are any bony bridges they are rare and small, sometimes with a trace of the original suture still evident.

3. *Partially obliterated*: The suture is partially obscured. There is no trace of the original suture in the bony bridges.

4. *Punctuated*: Only remnants of the suture are present. They appear as scattered small points or grooves each no more than two millimeters long.

5. *Obliterated*: There is no evidence of a suture.

## Sagittal Obelica

### Location

Score the relatively straight part of the posterior sagittal suture near the parietal foramina. This *ca.* 3-4 cm long segment is in the vicinity of the parietal foramina.

### Characteristics

1. Open
2. Juxtaposed
3. Partially obliterated
4. Punctuated
5. Obliterated

### Definitions

1. *Open*: The suture is visible along its entire length, and there is a noticeable gap between the bones.

2. *Juxtaposed*: The suture is visible along its entire length, but the suture is narrow because the bones are tightly juxtaposed. If there are any bony bridges they are rare and small, sometimes with a trace of the original suture still evident.

3. *Partially obliterated*: The suture is partially obscured. There is no trace of the original suture in the bony bridges.

4. *Punctuated*: Only remnants of the suture are present. They appear as scattered small points or grooves each no more than two millimeters long.

5. *Obliterated*: There is no evidence of a suture.

## **Lambdoidal Asterica**

### *Location*

The relatively straight part of the lambdoidal suture adjacent to asterion is scored.

### *Characteristics*

1. Open
2. Juxtaposed
3. Partially obliterated
4. Punctuated
5. Obliterated

### *Definitions*

1. *Open*: The suture is visible along its entire length, and there is a noticeable gap between the bones.

2. *Juxtaposed*: The suture is visible along its entire length, but the suture is narrow because the bones are tightly juxtaposed. If there are any bony bridges they are rare and small, sometimes with a trace of the original suture still evident.

3. *Partially obliterated*: The suture is partially obscured. There is no trace of the original suture in the bony bridges.

4. *Punctuated*: Only remnants of the suture are present. They appear as scattered small points or grooves each no more than two millimeters long.

5. *Obliterated*: There is no evidence of a suture.

## **Zygomaticomaxillary**

### *Location*

The entire length of the facial, or anterior, part of the zygomaticomaxillary suture is scored.

### *Characteristics*

1. Open
2. Juxtaposed
3. Partially obliterated
4. Punctuated
5. Obliterated

### *Definitions*

1. *Open*: The suture is visible along its entire length, and there is a noticeable gap between the bones.

2. *Juxtaposed*: The suture is visible along its entire length, but the suture is narrow because the bones are tightly juxtaposed. If there are any bony bridges they are rare and small, sometimes with a trace of the original suture still evident.

3. *Partially obliterated*: The suture is partially obscured. There is no trace of the original suture in the bony bridges.

4. *Punctuated*: Only remnants of the suture are present. They appear as scattered small points or grooves each no more than two millimeters long.

5. *Obliterated*: There is no evidence of a suture.

## **Interpalatine (Median Palatine, Posterior Portion)**

### *Location*

The suture located between the two opposing palatine bones is of interest. The Open (1) and Juxtaposed (2) distinction is not important because it is difficult to impossible to differentiate the two categories consistently. To keep scoring consistent across all sutures to make it easier for users and to reduce scoring error, the Juxtaposed (2) category is simply eliminated for this suture.

A small bony crest that often forms along the midline of the palate can make it difficult to record the extent of suture closure. In other specimens, the suture is barely visible in the depths of a deep and

narrow groove. Both the ridge and groove make it hard or impossible to score the suture.

#### *Characteristics*

1. Open (open and juxtaposed)
3. Partially obliterated
4. Punctuated
5. Obliterated

#### *Definitions:*

*1. Open (and juxtaposed):* The suture is visible along its entire length, and there is a noticeable gap between the bones.

*3. Partially obliterated:* The suture is partially obscured. There is no trace of the original suture in the bony bridges.

*4. Punctuated:* Only remnants of the suture are present. They appear as scattered small points or grooves each no more than two millimeters long.

*5. Obliterated:* There is no evidence of a suture.



## Pubic Symphysis

Five separate components are examined for the pubic symphysis. The various features are based on previous descriptions of bony changes in the pubic bone, especially those of Todd (1920) and McKern and Stewart (1957), supplemented by observations of numerous North American and Danish archaeological skeletons. Many terms used here are derived from this earlier work.

Users of Transition Analysis can gain experience with the changes that take place in the pubic symphysis by closely examining the excellent casts in the McKern-Stewart and Suchey-Brooks pubic bone sets. For sake of convenience, the several parts of the roughly oval symphyseal face are described as superior, inferior, ventral (anterior), and dorsal (posterior), even though such terms are not entirely accurate when the bone is oriented in proper anatomical position.

Opposing pubic bones tend to resemble one another, but they often differ in specific details. Therefore, the left and right sides are scored separately to accommodate that variation.

## Symphyseal Relief

### Location

The terms for this feature generally follow those of McKern and Stewart (1957). Although the entire face should be considered, the billowing is typically most clearly seen in the dorsal half of the symphyseal face. In fact, low ridges of bone, the billowing, can be entirely absent from the ventral symphyseal face, beginning as early as the ventral beveling stage.

### Characteristics

1. Sharp billowing
2. Soft, deep billowing
3. Soft, shallow billowing
4. Residual billowing
5. Flat
6. Irregular

### Definitions

*1. Sharp billowing:* Sharply crested ridges of bone cover at least half of the surface. Deep and distinct furrows that extend completely across the symphyseal face separate and typically well-

defined ridges. The deepest furrows cut into the ventral and dorsal margins of the symphyseal face, often interrupting the edge of the bone and giving it a jagged appearance. Sharp Billowing has only been seen in teenagers or in very young adults.

*2. Soft, deep billowing:* Softly crested to low billows separated by deep furrows extend across at least half of the surface, typically the dorsal half (demiface). The furrows do not appear as if they have been filled in with bone. The depth between high and low points of adjacent ridges and furrows is 2 mm or more.

*3. Soft, shallow billowing:* Low but clearly visible and discrete billows separated by shallow furrows are present on at least half of the dorsal demiface. The remnants of an earlier ridge and furrow system dominate the dorsal demiface, and the furrows look as if they were partially filled with bone. Billows occupy most or all of the dorsal demiface, and in some individuals they extend anteriorly to reach the ventral margin.

*4. Residual billowing:* Billows are barely visible, being only slightly elevated above the symphyseal face. They tend to blend into one another to form low and indistinct raised areas that lack clearly defined furrows between them. The slightly raised areas occupy only part of the symphyseal face, typically about one-third of the middle to inferior portions of the dorsal demiface. Individual billows usually cross only part of the symphyseal face, typically less than one-half its width, being concentrated on the dorsal portion. There must be two or more adjacent raised areas corresponding to billows to qualify as Residual Billowing. A single isolated bony elevation is not sufficient to be classified as Residual Billowing; instead, such specimens are considered Flat.

*5. Flat:* More than one-half of the symphyseal face within well-defined margins is flat or slightly recessed, and is often surrounded by a well-developed Rim. Occasionally small, low pillows of bone give the otherwise flat surface a slightly bumpy appearance, but the symphyseal face does not conform to Residual Billowing (i.e., there is no more than one discrete and well defined low raised area corresponding to what had been a more extensive series of billows). If there is a gap where the ventral rampart has failed to extend along the

entire ventral edge of the pubis (a ventral hiatus), the surface within the gap does not receive a score.

6. *Irregular*: Pitting, which can be deep, covers more than one-half of the symphyseal face, giving it an irregular and disfigured appearance. The pits can be accompanied by small, sharp exostoses scattered across the face. Occasionally, in old people an otherwise flat face is thickly covered by low but typically sharp exostoses that give the symphyseal surface a markedly irregular appearance. Pitting in such specimens might be minor, but the bone is still classified as Irregular. Similar to the Flat category, the scored part of the symphyseal face does not include the ventral gap, if present. In Irregular specimens, the margins of the symphyseal face are typically defined by the Rim and Breakdown stages of the Ventral and Dorsal Margin components.

## **Dorsal Symphyseal Texture**

### *Location*

The dorsal portion of the surface is examined.

### *Characteristics*

1. Smooth (fine grained)
2. Coarse grained
3. Microporosity
4. Macroporosity

### *Definitions*

1. *Smooth (fine grained)*: Smooth to fine-grained bone extends across most, or all, of the dorsal demiface.

2. *Coarse grained (little net)*: Coarse-textured bone covers over one-third of the dorsal demiface. The surface looks like packed fine sand, similar to medium-grained sandpaper. Americans will perhaps recognize it best as the surface of a sugar cube.

3. *Microporosity*: Porous bone covers over one-third of the dorsal demiface. It looks as if the surface was pierced by closely packed pin pricks.

4. *Macroporosity*: Deep pits cover over one-third of the dorsal demiface, giving it an irregular appearance. The pits are at least 0.5 mm in diameter, and are generally spaced close together. Sometimes the symphyseal surface is so irregular from pitting that it resembles the edge of a sponge.

The surface looks as if it was pierced by closely packed pin heads (the bulbous end of the same shirt or blouse pin in the previous description).

### *Scoring Tips*

The ventral part of the bone, when ventral beveling is present, is often pitted, giving it the appearance of microporosity. A porous appearing ventral portion (demiface) should not be confused with whatever is happening in the dorsal portion (demiface).

It is our impression that prehistoric Native American skeletons have microporosity more often and at an earlier age than medieval Scandinavians. More importantly, they differ from modern people in the Terry and Coimbra collections used to generate the transition curves used to estimate age. Therefore, it is best not to rely heavily on this component when examining Native American skeletons. In fact, it is prudent to record Symphyseal Texture stages for Native Americans, but treat them as missing data.

## **Superior Protuberance**

### *Location*

The superior part of the symphyseal face is examined for a distinct knob of bone or, later, an elevated area.

### *Characteristics*

1. No protuberance
2. Early protuberance
3. Late protuberance
4. Integrated

### *Definitions*

1. *No protuberance*: Deep to shallow billowing is present in the superior part of the symphyseal face. There are no signs of a bony protuberance. In young individuals, this part of the symphyseal face can be poorly differentiated from the non-articular portion of the pubis immediately lateral to the joint. This stage is on a symphyseal face characterized by a youthful ridge-and-valley surface.

2. *Early protuberance*: A distinct bony knob of variable dimensions with well-defined margins is visible in the superior part of the symphyseal face. It projects above the plane(s) defined by the

immediately adjacent symphyseal face (i.e., the superior portions of the dorsal and ventral demifaces, where the latter can be characterized by ventral beveling). The surface of the bony protuberance is typically smooth to fine grained. The bony knob often reminds one of a split pea stuck on the bone.

3. *Late protuberance*: The superior part of the symphyseal face is raised somewhat above the rest of the articulation surface. The elevated area is typically located mostly on the ventral side of the midline. The margins of the slightly raised area are poorly defined. These raised areas tend to look like a continuation of a relatively smooth symphyseal surface, except they slope slightly upward to meet the superior margin of the bone. Thus the Late Protuberance is more completely integrated with the rest of the symphyseal face than the distinctly knob-like Early Protuberance. Late Protuberance should not be confused with a narrow raised marginal rim that can border the cranial end of the symphyseal face in many specimens, especially females with narrow pubic symphyses. For a Late Protuberance to be scored as present, the slightly raised area must extend onto the symphyseal face; that is, it is not restricted to the rim alone. Occasionally, the superior part of the symphyseal face can be partly separated from the rest of the face by marked and extensive pitting of the middle symphyseal surface. Care must be taken not to confuse an isolated segment of the symphyseal face with a Late Protuberance stage. It is only Late Protuberance if the superior end of the symphyseal surface is elevated above the portions of the face not affected by the pitting.

4. *Integrated*: The symphyseal face's superior end displays no signs of a low bony elevation. The area where the protuberance was formerly present is fully integrated with the rest of the symphyseal face. That is, the smooth to irregular (usually pitted) symphyseal face is essentially flat. This stage, the absence of a raised area, is distinguishable from Stage 1, No Protuberance, because the superior portion of the symphyseal face is flat, not the ridge-and-valley surface typical of the initial No Protuberance stage. The Integrated stage also frequently has a narrow elevated rim demarcating the superior symphyseal surface, which is a continuation of the ventral or dorsal rims.

### *Scoring Tips*

Do not confuse a narrow rim bordering the superior margin of the symphyseal face, which commonly occurs in the terminal Integrated stage, with the earlier Late Protuberance stage. The two stages are distinguishable because the Late Protuberance raised area extends onto the upper part of the symphyseal face. In the Integrated stage, a flat symphyseal face extends up to, and abuts, a narrow rim, which is commonly present.

Occasionally, a gap exists in the superior one-half of the ventral margin, but the ventral rampart is otherwise completely formed. In that case, the presence of a protuberance is often not scored as the appearance of the bone can be confusing.

## **Ventral Symphyseal Margin**

### *Location*

The ventral margin of the pubic symphysis is scored separately from the rest of the bone.

### *Characteristics*

1. Serrated
2. Beveled
3. Rampart formation
4. Rampart completion with anterior sulcus
5. Rampart completion without sulcus
6. Rim
7. Breakdown

### *Definitions*

1. *Serrated*: Ridges and furrows typical of Sharp or Soft Deep Billowing extend uninterrupted across the ventral part of the symphyseal face, producing a serrated or jagged ventral margin, especially when viewed from the front of the bone.

2. *Beveled*: Billows are flattened in the ventral half of the symphyseal face, a process that generally starts at the superior end. The flattening, or beveling, must extend along at least one-third of the ventral margin to be scored as present. There is generally a well-defined margin where the ventral surface of the pubis (the beveled part) meets the articular surface located immediately posterior to it.

3. *Rampart incomplete*: The ventral rampart, following McKern and Stewart (1957), refers to a distinct outgrowth of bone that ultimately forms the

ventral aspect of the symphyseal face. The rampart extends from one or both ends of the symphysis, and it often resembles a roll of well-chewed gum stuck on the ventral edge of the symphyseal face. The rampart does not extend along the entire ventral edge, and often some elements of a youthful symphyseal surface can be followed uninterrupted to the ventral edge of the symphysis. In the superior part of the ventral margin, the rampart forms on the Beveled surface. In the inferior part of the margin, remnants of the original irregular surface can often be seen dipping below a partially formed rampart, which looks as if it was lying on a shallowly furrowed surface. An incomplete rampart frequently extends inferiorly from the bony protuberance defining the cranial end of the face, sometimes forming a bony elevation that resembles a comma, with the rampart being the tail.<sup>1</sup> A rampart can also extend superiorly from the inferior end of the symphysis. Bony extensions from the superior and inferior ends of the symphysis, if both are present, typically leave a gap in the middle one-third of the ventral margin. An early Rampart Incomplete stage can consist of one or more bony knobs, commonly located in the middle one-third of the ventral margin. The knobs can occur with, or without, the formation of a bony rampart extending from the superior and inferior ends of the symphysis. If the rampart is more than two-thirds complete but there is a gap in the superior part of it, you should consider the possibility that the specimen is in the Rampart Complete I or II stages. Occasionally a rampart never completely forms along the ventral margin.

*4. Rampart complete with anterior sulcus:* Rampart Complete 4 and 5 are similar to one another. What distinguishes them is the appearance of the anterior surface of the bone immediately lateral to the symphyseal margin. In Rampart Complete 4, the ventral rampart is complete, but there is a shallow sulcus extending along much of the length of the ventral pubis immediately lateral to the symphysis (often more pronounced inferiorly). The groove is a residual feature related to rampart formation along the ventral margin. A reasonably flat symphyseal surface extends uninterrupted from the dorsal to ventral margins, so the face is unlike the somewhat furrowed

appearance of many Rampart Incomplete specimens where there is a shallow groove just dorsal to an incomplete ventral rampart. Occasionally a gap exists in the ventral margin, usually in its superior half; the ventral rampart is otherwise completely formed. This stage is only occasionally found in most skeletal samples that have been examined. Typically the completed rampart is a Stage 5, Rampart Complete Without Sulcus. The only difference between Stages 4 and 5 is the presence of the anterior sulcus in Stage 4.

*5. Rampart complete without sulcus:* The ventral rampart is complete, and there is no shallow sulcus as described in Rampart Complete 4. A reasonably flat symphyseal surface extends uninterrupted from its dorsal to ventral margins, so the face is unlike the somewhat furrowed appearance of many Rampart Incomplete specimens where there is also a shallow groove just dorsal to the incomplete ventral rampart. Occasionally there is a gap in the superior half of the ventral margin, but the ventral rampart is otherwise complete. These specimens should be classified as Rampart Complete. With regard to Rampart Complete With and Without Anterior Sulcus (Stages 4 and 5), most specimens are in the later Stage 5.

*6. Rim:* A narrow, bony rim defining the ventral margin of the symphysis, perched on top of the ventral rampart, demarcates a usually flat or irregular face. The rim does not have to be complete, but it must be at least 1 cm long and readily visible as a raised ridge adjacent to a slightly recessed symphyseal face. The rim can be either a continuous ridge of bone or several segments, as long as 1 cm of an elevated border is present. The rim's crest can be low and rounded, or narrow and sharp. A ventral rim is always formed on top of a ventral rampart. Odd rim-like bone formations on gaps in a rampart or formed with no rampart at all are *not* scored as a ventral rim.

*7. Breakdown:* The ventral margin of the symphyseal face has begun to break down, as indicated by pitting and an erosion of the Rim. The breakdown of the ventral margin must exceed 1 cm (either in one spot, or when two or more areas of erosion are combined) to be scored as present. Care must be taken to distinguish antemortem degeneration – that is, true Breakdown – from postmortem damage. The latter, of course, can render the bone unscorable if it is extensive enough.

<sup>1</sup> A well-developed bony protuberance at the cranial end of the face that lacks a distinct inferiorly projecting ventral rampart should not be coded as Ventral Rampart Formation; that is, the mere existence of a cranially located bony knob without bone being laid down along the ventral margin is not sufficient to score the ventral rampart as present.

### Scoring Tips

In mature pubic symphyses there can be a gap in the ventral margin, as noted by McKern and Stewart (1957: 77, Fig. 40) who called it the “ventral hiatus.” Gaps, when present, usually occur in the superior half of the pubic symphysis. In most instances, they are readily distinguishable from incomplete rampart formation because the remainder of the ventral rampart appears complete. That is, the ventral margin elsewhere has a rounded to angular edge, an anterior sulcus is typically absent, and a rim might have developed on the part of the rampart that is present. In addition, the symphyseal surface extends uninterrupted from the dorsal to ventral margins, and it is often flat. The appearance of the symphyseal face contrasts sharply with what is present in the typical Rampart Incomplete stage. In the earlier Rampart Incomplete stage, a shallow depression is often present immediately dorsal to the newly formed and still rather narrow rampart, and much of the rest of the symphyseal face is marked by remnants of the original ridges and furrows.

Occasionally in the Rim or Breakdown stages, there is also a separate bony growth or collar, presumably ossified ligaments, adjacent to the ventral margin that is separated from the symphyseal face by a groove. It only occurs on old people, and it is more commonly found toward the superior end of the pubic symphysis. This bony structure is not scored and should not to be confused with what is happening on the symphyseal surface or its margin.

## Dorsal Symphyseal Margin

### Location

The dorsal part of the pubic symphysis is scored separately from the ventral margin. In females, dorsally located characteristics can be partly or entirely obscured by large postpartum, or parity, pits. Occasionally, such specimens cannot be scored properly.

### Characteristics

1. Serrated
2. Flattening incomplete
3. Flattening complete
4. Rim
5. Breakdown

### Definitions

1. *Serrated*: The dorsal margin of the symphyseal face is irregular because ridges and furrows typical of pronounced billowing extend uninterrupted to the edge of the bone.

2. *Flattening incomplete*: A well-defined flattened area at least 1 cm long is present where the symphyseal face meets the dorsal margin. Flattening usually starts in the superior part of the dorsal demiface; the remainder of the margin has the ridge and valley configuration typical of a youthful symphyseal face. The undulating edge usually occurs in the inferior part of the symphyseal face. Note that billowing is also present on the dorsal demiface, and it typically produces an undulating edge to the pubic symphysis, although it is typically not as extreme as what is found in Serrated specimens.

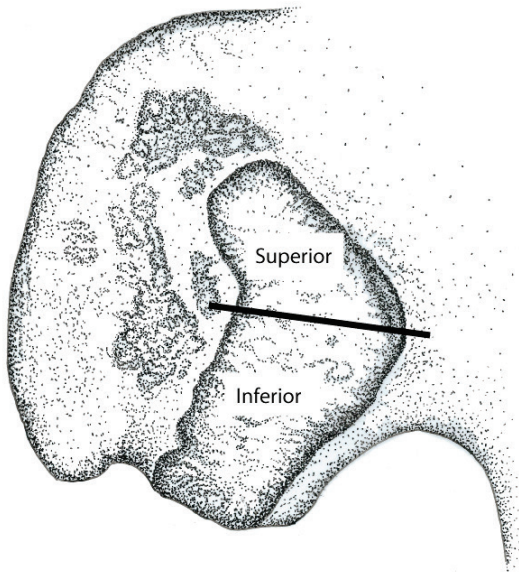
3. *Flattening complete*: There is a rather obvious area of flattening that completely (or almost entirely) covers the symphyseal face where it meets the dorsal margin. This flattening seemingly occurs partly through a coalescence of billows. A small area at the inferior end of the dorsal margin occasionally retains an undulating appearance.

4. *Rim*: An elevated bony rim demarcates a flat or, infrequently, an irregular face. The rim projects slightly above the symphyseal face, and its crest can be blunt or sharp. The rim does not have to extend along the entire dorsal margin to be scored as present, but it must be at least 1 cm long. The 1 cm rule pertains to either a continuous rim or discontinuous segments that together sum to that length. A rim typically develops first along the superior part of the dorsal margin. It can, however, occur anywhere along the dorsal margin.

5. *Breakdown*: The dorsal margin where the Rim is located shows evidence of breakdown, specifically a pitting and erosion of the edge of the pubic symphysis. The breakdown must exceed 1 cm in length either in one spot or when two or more areas of erosion are combined. Care must be taken to differentiate antemortem degeneration of the margin from postmortem damage, which is of no concern. Antemortem destruction attributable to large parity pits in females that can undercut the dorsal margin is not considered breakdown in the sense of the term as used here. It might not be possible to score those specimens; when that occurs, the component is simply missing data.

## Sacroiliac Joint

Two aspects of the sacroiliac joint on the ilium are examined: the auricular (joint) surface, and the ilium immediately posterior to the joint surface. Anatomical features and terms follow those of Lovejoy and colleagues (1985) where possible.



### Superior Demiface Topography

#### Location

The superior demiface is examined. The two demifaces are divided by a line extending posteriorly from the most anterior point of the apex to the posterior joint margin.

#### Characteristics

1. Undulating
2. Median elevation
3. Flat to Irregular

#### Definitions

*1. Undulating:* The surface is undulating in a superior to inferior direction. There is no centrally located and linear area of elevated bone (Median Elevation). When the entire articulation surface is viewed in aggregate, the overall effect is of two or three low waves proceeding lengthwise along the joint.

*2. Median elevation:* In the middle to posterior part of the demiface there is a broad raised area where the joint surface is elevated slightly above the rest of the joint. The elevation is flanked anteriorly, posteriorly, or both by one or two long low areas. The elevated area takes the form of an elongated ridge with the long axis paralleling the main orientation of the demiface. It is not unusual for the elevated area to be restricted to a noticeably raised area that does not extend the entire length of the demiface. When that occurs, the raised area is typically located in the inferior portion of the demiface. To be scored as present, the elevated area must extend along at least one-third of the joint surface's length.

*3. Flat to irregular:* The surface is essentially flat or recessed, a result of marginal lipping, or it is irregular from degeneration of the joint or the formation of low pillow-like exostoses.

#### Scoring Tips

These comments pertain equally to both Superior and Inferior Demiface Topography. The first thing to do is to place your thumb such that it masks the superior demiface, and then score the inferior part of the joint. The characteristics of the inferior part are generally easier to see, and to score reliably, than the superior part, especially with regard to the Median Elevation. Then move your thumb so it masks much of the inferior part of the joint so you just look at the superior end. The purpose of this exercise is to prevent being unduly influenced by what is happening in the part of the joint that is not being scored.

When deciding which of the stages is represented, it is easiest to first determine if a Median Elevation is present. It will generally be more pronounced on the inferior demiface. If it is not present, typically the surface is in the Flat to Irregular stage. The Undulating variant is almost always found on the ilia of young people in their teens or twenties. The Superior Demiface Undulating and Median Elevation features are typically more subdued and harder to distinguish than those of the Inferior Demiface.

In short, most specimens are either Median Elevation (2) or Flat to Irregular (3).

Occasionally in young adults a median elevation appears to be in the process of forming on an otherwise undulating surface. The median elevation is short and typically centrally located on

the superior demiface (rarely this occurs on the inferior demiface). Because the median elevation, if it is indeed present, is poorly defined, these specimens are best coded as 1-2.

## Inferior Demiface Topography

### *Location*

The inferior demiface is examined. The superior and inferior demifaces are divided by a line extending posteriorly from the most anterior point of the apex to the posterior border of the joint.

### *Characteristics*

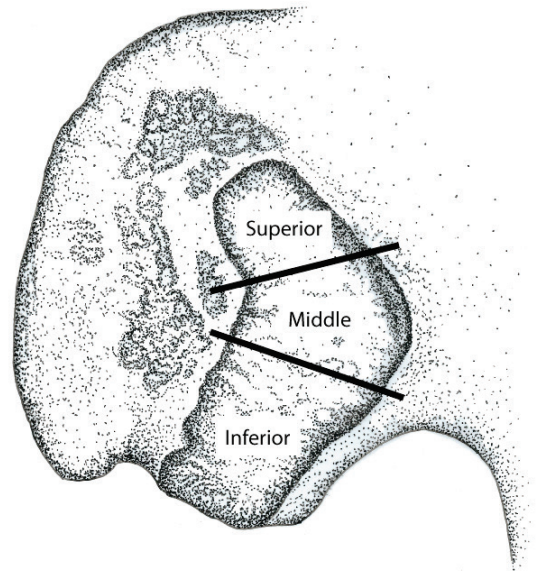
1. Undulating
2. Median elevation
3. Flat to Irregular

### *Definitions*

1. *Undulating*: The surface is undulating in a superior to inferior direction. There is no centrally located and linear area of elevated bone (Median Elevation). When the entire articulation surface is viewed in aggregate, the overall effect is of two or three low waves proceeding lengthwise along the joint.

2. *Median elevation*: In the middle to posterior part of the demiface there is a broad raised area where the joint surface is elevated slightly above the rest of the joint. The elevation is flanked anteriorly, posteriorly, or both by one or two long low areas. The elevated area takes the form of an elongated ridge with the long axis paralleling the main orientation of the demiface. It is not unusual for the elevated area to be restricted to a noticeably raised area that does not extend the entire length of the demiface. To be scored as present, the elevated area must extend along at least one-third of the joint surface's length.

3. *Flat to irregular*: The surface is essentially flat or recessed, a result of marginal lipping, or it is irregular, from degeneration of the joint or the formation of low pillow-like exostoses.



## Superior Surface Characteristics

### *Location*

The superior part of the face is examined. The joint surface is divided into superior, middle (apical), and inferior segments.

### *Characteristics*

1.  $>2/3$  covered by billows
2.  $1/3$ - $2/3$  covered by billows
3.  $<1/3$  covered by billows
4. Flat (no billows)
5. Bumps

### *Definitions*

1. *Billows cover  $>2/3$  of the surface*: Low rounded ridges separated by furrows, which have distinctly rounded bases, are clearly identifiable. The ridge surfaces are curved from the depths of the furrows completely across their crests. Most or all of the billowing is oriented roughly anterior to posterior, and furrows can run across much of the face. Billowing covers most ( $>2/3$ ) of the joint surface (i.e., it is a dominant element of the surface).

2. *Billows cover  $1/3$ - $2/3$  of the surface*: About one-half of the surface is covered by billows.

3. *Billows cover <1/3 of the surface*: Billows are a noticeable, but minor, component of the joint surface. The rest of the surface is flat or bumpy.

4. *Flat (no billows)*: The joint surface is flat.

5. *Bumps*: Most, or all, of the joint surface is covered by low, rounded bony exostoses, much like little irregular pillows. Part of the surface may be flat, but over one-half of it is bumpy. One is often reminded of lentils squished onto the joint surface. The bumps can be discrete low elevations or confluent, in which case the raised areas have irregular margins.

*Unscorable*: If defects in the joint surface are so extensive they obscure much of the face, this characteristic is considered unscorable. The defects often take one of two forms. Irregular and large pits can be present that are for the most part either separate or confluent with one another. The pits can be found anywhere on the joint face. Alternatively, the defects are linear grooves that occur in isolation or as multiple nearby grooves. In either case, they can be up to a centimeter long, and they generally extend more or less in a transverse direction. For the linear defects in particular, the smooth bone of the joint surface frequently laps over into the defect for a short distance. That is, the lips of these defects are covered by smooth-surfaced bone. The grooves are more commonly found in the middle part of the joint surface than toward the superior or inferior ends. They are not to be confused as some form of anomalously deep billows. Occasionally surface defects are sufficient to obscure the Superior and Inferior Demiface Topography, although they more often interfere with the proper scoring of the Superior, Middle, and Inferior Surface Characteristics.

#### *Scoring Tips*

These comments pertain to the Superior, Middle, and Inferior Surface Characteristics. The best way to proceed is to first bracket the part of the auricular surface that includes the apex with your two thumbs. That defines the middle, or apical, portion. Then move one thumb to define the inferior margin of the superior portion. Finally, use a thumb to define the superior margin of the inferior surface. This simple masking procedure will help counteract the tendency to be influenced by what is present on adjacent parts of the auricular surface.

When scoring the surface characteristics, it is generally easiest to first look for billows. If present, then determine how abundant they are: there are only a few of them, they cover roughly one-half of the surface, or they spread out across much of the surface. If billows are not present, then look for bumps. The low and irregular bumps do not display the generally transverse organization of the billows.

## **Middle Surface Characteristics**

### *Location*

The middle part of the face is examined. This area corresponds to the portion of the joint surface that includes the so-called apex – the "bend" in the boomerang-shaped auricular surface.

### *Characteristics*

1. >2/3 covered by billows
2. 1/3-2/3 covered by billows
3. <1/3 covered by billows
4. Flat (no billows)
5. Bumps

### *Definitions*

1. *Billows cover >2/3 of the surface*: Low rounded ridges separated by furrows, which have distinctly rounded bases, are clearly identifiable. The ridge surfaces are curved from the depths of the furrows completely across their crests. Most or all of the billowing is oriented roughly anterior to posterior, and furrows can run across much of the face. Billowing covers most (>2/3) of the joint surface (i.e., it is a dominant element of the surface).

2. *Billows cover 1/3-2/3 of the surface*: About one-half of the surface is covered by billows.

3. *Billows cover <1/3 of the surface*: Billows are a noticeable, but minor, component of the joint surface. The rest of the surface is flat or bumpy.

4. *Flat (no billows)*: The joint surface is flat.

5. *Bumps*: Most, or all, of the joint surface is covered by low, rounded bony exostoses, much like little irregular pillows. Part of the surface may be flat, but over one-half of it is bumpy. One is often reminded of lentils squished onto the joint surface. The bumps can be discrete low elevations



or confluent, in which case the raised areas have irregular margins.

*Unscorable*: If defects in the joint surface are so extensive they obscure much of the face, this characteristic is considered unscorable. The defects often take one of two forms. Irregular and large pits can be present that are for the most part either separate or confluent with one another. The pits can be found anywhere on the joint face. Alternatively, the defects are linear grooves that occur in isolation or as multiple nearby grooves. In either case, they can be up to a centimeter long, and they generally extend more or less in a transverse direction. For the linear defects in particular, it frequently appears as if the smooth bone of the joint surface laps over into the defect for a short distance. The grooves are more commonly found in the middle part of the joint surface than toward the superior or inferior ends. They are not to be considered as some form of anomalously deep billows. Occasionally the surface defects are sufficient to obscure the Superior and Inferior Demiface Topography, although they more often interfere with the proper scoring of the Superior, Middle, and Inferior Surface Characteristics.

## Inferior Surface Characteristics

### Location

The inferior part of the face is examined. On most ilia, this is the largest part of the auricular surface as it is defined here.

### Characteristics

1.  $>2/3$  covered by billows
2.  $1/3$ - $2/3$  covered by billows
3.  $<1/3$  covered by billows
4. Flat (no billows)
5. Bumps

### Definitions

1. *Billows cover  $>2/3$  of the surface*: Low rounded ridges separated by furrows, which have distinctly rounded bases, are clearly identifiable. The ridge surfaces are curved from the depths of the furrows completely across their crests. Most or all of the billowing is oriented roughly anterior to posterior, and furrows can run across much of the face. Billowing covers most ( $>2/3$ ) of the joint surface (i.e., it is a dominant element of the surface).

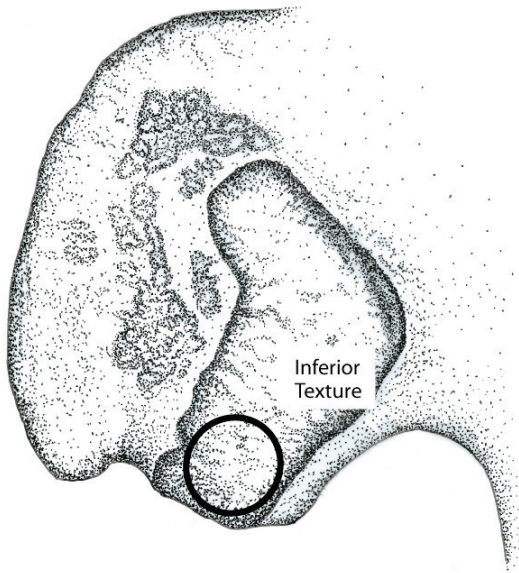
2. *Billows cover  $1/3$ - $2/3$  of the surface*: About one-half of the surface is covered by billows.

3. *Billows cover  $<1/3$  of the surface*: Billows are a noticeable, but minor, component of the joint surface. The rest of the surface is flat or bumpy.

4. *Flat (no billows)*: The joint surface is flat.

5. *Bumps*: Most, or all, of the joint surface is covered by low, rounded bony exostoses, much like little irregular pillows. Part of the surface may be flat, but over one-half of it is bumpy. One is often reminded of lentils squished onto the joint surface. The bumps can be discrete low elevations or confluent, in which case the raised areas have irregular margins.

*Unscorable*: If defects in the joint surface are so extensive they obscure much of the face, this characteristic is considered unscorable. The defects often take one of two forms. Irregular and large pits can be present that are for the most part either separate or confluent with one another. The pits can be found anywhere on the joint face. Alternatively, the defects are linear grooves that occur in isolation or as multiple nearby grooves. In either case, they can be up to a centimeter long, and they generally extend more or less in a transverse direction. For the linear defects in particular, it frequently appears as if the smooth bone of the joint surface laps over into the defect for a short distance. The grooves are more commonly found in the middle part of the joint surface than toward the superior or inferior ends. They are not to be considered as some form of anomalously deep billows. Occasionally the surface defects are sufficient to obscure the Superior and Inferior Demiface Topography, although they more often interfere with the proper scoring of the Superior, Middle, and Inferior Surface Characteristics.



### Inferior Surface Texture

#### Location

Only one part of the joint surface – the inferior area – is scored for texture. This part of the joint is 1 cm long, as measured in a superior to inferior direction. Occasionally there can be an elongated portion of the joint surface, often accompanied by marginal lipping, that can extend well beyond the main body of the ilium. While it can occur in both sexes, it is more often seen in females. Do not score the auricular surface that extends beyond the margin of the ilium proper.

#### Characteristics

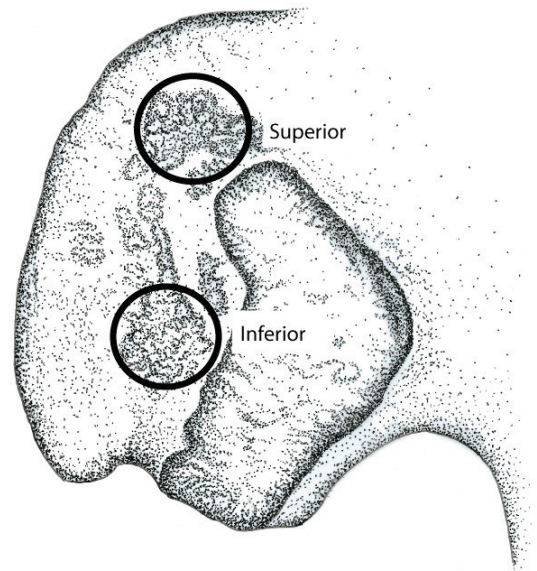
1. Smooth
2. Microporosity
3. Macroporosity

#### Definitions

*1. Smooth:* Most, or all, of the joint surface appears to be smooth to slightly granular.

*2 Microporosity:* At least one-half of the surface has a porous appearance with apertures less than 0.5 mm in diameter. The symphyseal face looks as if it is covered by many closely spaced pinpricks.

*3. Macroporosity:* At least one-half of the surface is porous, with most, or all, of the apertures exceeding 0.5 mm in diameter. Here the surface looks as if it was penetrated by multiple closely spaced pin heads (the large end of the same shirt pin mentioned above).



### Superior Posterior Iliac Exostoses

#### Location

Superior posterior iliac exostoses are scored. This area refers to the superior part of the medial surface of the posterior ilium where ligaments attach. It is located superior to the sacroiliac joint surface; that is, to a line that passes from the anterior superior iliac spine, to the most superior point of the joint surface (the superior angle), and on through the posterior part of the ilium. In some individuals, the bone is distinctly raised in this area. So care must be taken to differentiate jagged (or high) exostoses from rounded or pointed ones perched on top of a raised elevation of bone.

#### Characteristics

1. Smooth
2. Rounded exostoses
3. Pointed exostoses
4. Jagged exostoses
5. Touching exostoses
6. Fusion

### Definitions

1. *Smooth*: The surface is often elevated in this area, but shows no evidence of discrete bony elevations. At most there are one or two isolated small exostoses.

2. *Rounded exostoses*: Definite raised areas of bone with rounded crests dominate the scoring area.

3. *Pointed exostoses*: Over one-half of the rough area where ligaments attach is dominated by sharply pointed, but short, elevations of bone.

4. *Jagged exostoses*: The raised areas of bone have a jagged appearance where ligaments attach in life. These exostoses, which can have either round or sharp ends, are tall, extending several millimeters upward from the original bone surface.

5. *Touching exostoses or facet*: There is a distinct oval facet where the ilium and sacrum are in close juxtaposition, often 5 mm in diameter or more. This facet can occur either on top of a pronounced growth of bone or on an iliac surface that is relatively flat.

6. *Fusion*: The ilium and sacrum are fused by exostoses in this area.

### Scoring Tips

These comments pertain equally to the Superior and Inferior Posterior Iliac Exostoses.

If the ilium is fused to the sacrum at the margins of the auricular surface (usually the superior-anterior margin), you are well advised to score the Superior and Inferior Exostoses as not observable. The effect of fusion on the posterior exostoses is unknown.

The common adult condition is to have either Rounded or Pointed Exostoses. The Smooth variant is typically found on the ilia of only very young adults. You will rarely see sharp Jagged Exostoses.

## Inferior Posterior Iliac Exostoses

### Location

The inferior posterior iliac exostoses are scored. This area refers to the inferior part of the medial surface of the posterior ilium where ligaments attach. It is located inferior to a line that passes from the anterior superior iliac spine, to the

most superior point of the sacroiliac joint surface (the superior angle), and on through the posterior part of the ilium. This area is located immediately posterior to the middle of the sacroiliac joint; that is, it lies behind the most anteriorly projecting part of the posterior margin of the joint. In some individuals, the bone is distinctly raised in this area. So care must be taken to differentiate jagged (or high) exostoses from rounded or pointed ones perched on top of a raised elevation of bone.

### Characteristics

1. Smooth
2. Rounded exostoses
3. Pointed exostoses
4. Jagged exostoses
5. Touching exostoses
6. Fusion

### Definitions

1. *Smooth*: The surface is often elevated in this area, but shows no evidence of discrete bony elevations. At most there are one or two isolated small exostoses.

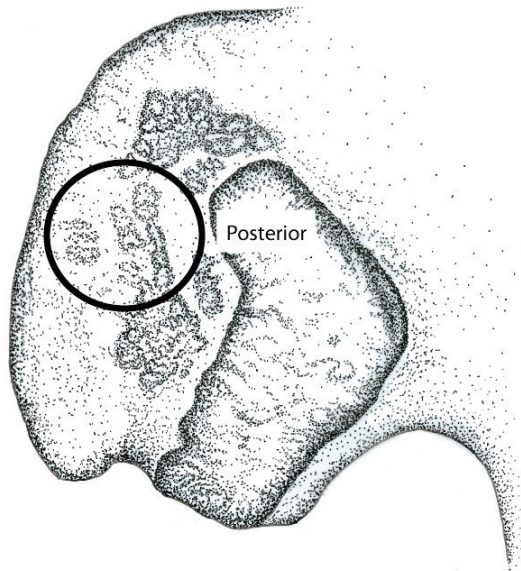
2. *Rounded exostoses*: Definite raised areas of bone with rounded crests dominate the scoring area.

3. *Pointed exostoses*: Over one-half of the rough area where ligaments attach is dominated by sharply pointed, but short, elevations of bone.

4. *Jagged exostoses*: The raised areas of bone have a jagged appearance where ligaments attach in life. These exostoses, which can have either round or sharp ends, are tall, extending several millimeters upward from the original bone surface.

5. *Touching exostoses or facet*: There is a distinct oval facet where the ilium and sacrum are in close juxtaposition, often 5 mm in diameter or more. This facet can occur either on top of a pronounced growth of bone or on an iliac surface that is relatively flat.

6. *Fusion*: The ilium and sacrum are fused by exostoses in this area.



## Posterior Exostoses

### Location

The posterior iliac area between the Superior and Inferior Posterior Iliac Exostoses, as defined above, are scored. The area where the exostoses occur is on the medial side of the ilium bordered posteriorly by the iliac crest, anteriorly by the sacroiliac joint surface, superiorly by a slightly raised area often surmounted by bony exostoses (Superior Posterior Iliac Exostoses), and inferiorly by a similar area (Inferior Posterior Iliac Exostoses). Most individuals are Smooth as defined below. The feature is best considered an old-age trait.

### Characteristics

1. Smooth (no exostoses)
2. Rounded exostoses
3. Pointed exostoses

### Definitions

1. *Smooth*: The area posterior to the sacroiliac joint is smooth, except for the two areas scored separately as Superior and Inferior Posterior Iliac Exostoses.

2. *Rounded exostoses*: Low, rounded exostoses (or spicules) cover the *entire* bone surface posterior to the sacroiliac joint, except for a

ca. 0.5 cm band of smooth bone immediately adjacent to the posterior edge of the joint. The exostoses are normally lower than the Superior and Inferior Posterior Iliac Exostoses. The low exostoses give the normally smooth iliac surface a rough appearance. It looks as if the surface is covered by coarse (construction) sand.

3. *Pointed exostoses*: Low, pointed exostoses (or spicules) cover the *entire* bone surface posterior to the sacroiliac joint, except for a ca. 0.5 cm band of smooth bone immediately adjacent to the posterior edge of the joint. The exostoses are normally lower than the Superior and Inferior Posterior Iliac Exostoses. The sharp exostoses give the normally smooth iliac surface a rough appearance. It looks as if the surface is covered by coarse (construction) sand.

### Scoring Tips

By far the most common condition is Smooth, as it is defined here. Keep in mind that the Smooth category also includes surfaces with bony exostoses, which are typical of the 20s onward. Bones are only scored as the Rounded or Pointed categories if the entire surface is covered with exostoses; that is, the surface looks as if it is thickly covered by construction sand (little, if any, of the original smooth surface remains visible). Furthermore, the ilium and sacrum can be fused in several places. If that occurs, you are well advised to score Posterior Exostoses as not observable, as the effect of fusion on this joint characteristic is unknown.

## References

- Boldsen JL, Milner GR, Konigsberg LW, Wood JW  
2002 Transition Analysis: A New Method for Estimating Age from Skeletons. In *Paleodemography: Age Distributions from Skeletal Samples*. Hoppa RD and Vaupel JW (eds), pp. 73-106. Cambridge University Press, Cambridge.
- Lovejoy CO, Meindl RS, Pryzbeck TR, Mensforth RP  
1985 Chronological Metamorphosis of the Auricular Surface of the Ilium: A New Method for the Determination of Adult Skeletal Age at Death. *American Journal of Physical Anthropology* 68:15-28.
- Mann RW, Symes SA, Bass WM  
1987 Maxillary Suture Obliteration: Aging the Human Skeleton Based on Intact or Fragmentary Maxilla. *Journal of Forensic Sciences* 32:148-157.
- McKern TW, Stewart TD  
1957 *Skeletal Age Changes in Young American Males*. Technical Report EP-45. Quartermaster Research and Development Center, US Army, Natick, Massachusetts.
- Milner GR, Boldsen JL  
2012 Transition Analysis: A Validation Study with Known-Age Modern American Skeletons. *American Journal of Physical Anthropology* 148:98-110.